

## Exempel på rct studier under 2007

Från [www.pubmed.com](http://www.pubmed.com) / sökord laser therapy

1: [Tanzan Health Res Bull](#). 2007 Sep;9(3):196-201. [Links](#)

### Low intensity laser therapy is comparable to bromocriptine-evening primrose oil for the treatment of cyclical mastalgia in Egyptian females.

[Saied GM](#), [Kamel RM](#), [Dessouki N](#).

Department of General Surgery, Faculty of Medicine, Cairo University, Egypt.

One of the successful treatments for cyclical mastalgia is bromocriptine evening primrose combination. A double blind study was applied on 80 patients with cyclical mastalgia. They were randomly divided into two groups (A and B). In group A, patients were treated by bromocriptine/evening primrose. To group B, LILT with specified dosimetry was applied, using a device that delivers He-Ne laser combined with 4 infra-red diode laser. Evaluation of treatment was both subjective (using VAS) and objective (studying the degree of drop in plasma cortisol level). The drop of plasma cortisol with treatment was studied using the student -t distribution. A good response was observed in the laser group in 82.5%, compared to 63.9% in the bromocriptine/evening primrose group. There was a significant deference before and after treatment in both groups ( $P < 0.05$ ). This difference was more for the drug treated group than for the laser treated group, but in the latter, it acted on a wider sector of patients. In conclusion, LILT is recommended as a new treatment modality for cyclical mastalgia.

PMID: 18087899 [PubMed - in process]

1: [J Hand Ther.](#) 2008 Jan-Mar;21(1):63-8. [Links](#)


## **The Short-term Efficacy of Laser, Brace, and Ultrasound Treatment in Lateral Epicondylitis: A Prospective, Randomized, Controlled Trial.**

[Oken O](#), [Kahraman Y](#), [Ayhan F](#), [Canpolat S](#), [Yorgancioglu ZR](#), [Oken OF](#).

Ankara Education and Research Hospital, Department of Physical Medicine and Rehabilitation, Division of Hand Rehabilitation, Ankara, Turkey.

The aims of this study were to evaluate the effects of low-level laser therapy (LLLT) and to compare these with the effects of brace or ultrasound (US) treatment in tennis elbow. The study design used was a prospective and randomized, controlled, single-blind trial. Fifty-eight outpatients with lateral epicondylitis (9 men, 49 women) were included in the trial. The patients were divided into three groups: 1) brace group-brace plus exercise, 2) ultrasound group-US plus exercise, and 3) laser group-LLLT plus exercise. Patients in the brace group used a lateral counterforce brace for three weeks, US plus hot pack in the ultrasound group, and laser plus hot pack in the LLLT group. In addition, all patients were given progressive stretching and strengthening exercise programs. Grip strength and pain severity were evaluated with visual analog scale (VAS) at baseline, at the second week of treatment, and at the sixth week of treatment. VAS improved significantly in all groups after the treatment and in the ultrasound and laser groups at the sixth week ( $p < 0.05$ ). Grip strength of the affected hand increased only in the laser group after treatment, but was not changed at the sixth week. There were no significant differences between the groups on VAS and grip strength at baseline and at follow-up assessments. The results show that, in patients with lateral epicondylitis, a brace has a shorter beneficial effect than US and laser therapy in reducing pain, and that laser therapy is more effective than the brace and US treatment in improving grip strength.

PMID: 18215753 [PubMed - in process]

□ 1: [Photomed Laser Surg.](#) 2007 Jun;25(3):205-13.  [Links](#)

## Effects of low-level laser and plyometric exercises in the treatment of lateral epicondylitis.

[Stergioulas A.](#)

Faculty of Human Movement & Quality of Life, Peloponnese University, Sparta, Greece.  
asterg@uop.gr

**OBJECTIVE:** This study was undertaken to compare the effectiveness of a protocol of combination of laser with plyometric exercises and a protocol of placebo laser with the same program, in the treatment of tennis elbow. **BACKGROUND DATA:** The use of low-level laser has been recommended for the management of tennis elbow with contradictory results. Also, plyometric exercises was recommended for the treatment of the tendinopathy. **METHODS:** Fifty patients who had tennis elbow participated in the study and were randomised into two groups. Group A (n = 25) was treated with a 904 Ga-As laser CW, frequency 50 Hz, intensity 40 mW and energy density 2.4 J/cm(2), plus plyometric exercises and group B (n = 25) that received placebo laser plus the same plyometric exercises. During eight weeks of treatment, the patients of the two groups received 12 sessions of laser or placebo, two sessions per week (weeks 1-4) and one session per week (weeks 5-8). Pain at rest, at palpation on the lateral epicondyle, during resisted wrist extension, middle finger test, and strength testing was evaluated using Visual Analogue Scales. Also it was evaluated the grip strength, the range of motion and weight test. Parameters were determined before the treatment, at the end of the eighth week course of treatment (week 8), and eighth (week 8) after the end of treatment. **RESULTS:** Relative to the group B, the group A had (1) a significant decrease of pain at rest at the end of 8 weeks of the treatment ( $p < 0.005$ ) and at the end of following up period ( $p < 0.05$ ), (2) a significant decrease in pain at palpation and pain on isometric testing at 8 weeks of treatment ( $p < 0.05$ ), and at 8 weeks follow-up ( $p < 0.001$ ), (3) a significant decrease in pain during middle finger test at the end of 8 weeks of treatment ( $p < 0.01$ ), and at the end of the follow-up period ( $p < 0.05$ ), (4) a significant decrease of pain during grip strength testing at 8 weeks of treatment ( $p < 0.05$ ), and at 8 weeks follow-up ( $p < 0.001$ ), (5) a significant increase in the wrist range of motion at 8 weeks follow-up ( $p < 0.01$ ), (6) an increase in grip strength at 8 weeks of treatment ( $p < 0.05$ ) and at 8 weeks follow-up ( $p < 0.01$ ), and (7) a significant increase in weight-test at 8 weeks of treatment ( $p < 0.05$ ) and at 8 weeks follow-up ( $p < 0.005$ ). **CONCLUSION:** The results suggested that the combination of laser with plyometric exercises was more effective treatment than placebo laser with the same plyometric exercises at the end of the treatment as well as at the follow-up. Future studies are needed to establish the relative and absolute effectiveness of the above protocol.

PMID: 17603862 [PubMed - in process]

1: [Photomed Laser Surg.](#) 2007 Apr;25(2):65-71.

Mary Ann Liebert,

[Links](#)

## Effects of 904-nm low-level laser therapy in the management of lateral epicondylitis: a randomized controlled trial.

[Lam LK](#), [Cheing GL](#).

Physiotherapy Department, Queen Elizabeth Hospital, Hong Kong.

**OBJECTIVE:** The aim of this study was to evaluate the effectiveness of 904-nm low-level laser therapy (LLLT) in the management of lateral epicondylitis. **BACKGROUND DATA:** Lateral epicondylitis is characterized by pain and tenderness over the lateral elbow, which may also result in reduction in grip strength and impairment in physical function. LLLT has been shown effective in its therapeutic effects in tissue healing and pain control. **METHODS:** Thirty-nine patients with lateral epicondylitis were randomly assigned to receive either active laser with an energy dose of 0.275 J per tender point (laser group) or sham irradiation (placebo group) for a total of nine sessions. The outcome measures were mechanical pain threshold, maximum grip strength, level of pain at maximum grip strength as measured by the Visual Analogue Scale (VAS) and the subjective rating of physical function with Disabilities of the Arm, Shoulder and Hand (DASH) questionnaire. **RESULTS:** Significantly greater improvements were shown in all outcome measures with the laser group than with the placebo group ( $p < 0.0125$ ), except in the two subsections of DASH. **CONCLUSION:** This study revealed that LLLT in addition to exercise is effective in relieving pain, and in improving the grip strength and subjective rating of physical function of patients with lateral epicondylitis.

PMID: 17508839 [PubMed - in process]

## **In chronic low back pain, low level laser therapy combined with exercise is more beneficial than exercise alone in the long term: a randomised trial.**

[Djavid GE](#), [Mehrdad R](#), [Ghasemi M](#), [Hasan-Zadeh H](#), [Sotoodeh-Manesh A](#), [Pouryaghoub G](#).

Occupational Medicine, Tehran University of Medical Sciences, Tehran, Iran.  
mehrdadr@tums.ac.ir.

Question: Is low level laser therapy an effective adjuvant intervention for chronic low back pain?  
Design: Randomised trial with concealed allocation, blinded assessors and intention-to-treat analysis. Participants: Sixty-one patients who had low back pain for at least 12 weeks.  
Intervention: One group received laser therapy alone, one received laser therapy and exercise, and the third group received placebo laser therapy and exercise. Laser therapy was performed twice a week for 6 weeks. Outcome measures: Outcomes were pain severity measured using a 10-cm visual analogue scale, lumbar range of motion measured by the Schober Test and maximum active flexion, extension and lateral flexion, and disability measured with the Oswestry Disability Index on admission to the study, after 6 weeks of intervention, and after another 6 weeks of no intervention. Results: There was no greater effect of laser therapy compared with exercise for any outcome, at either 6 or 12 weeks. There was also no greater effect of laser therapy plus exercise compared with exercise for any outcome at 6 weeks. However, in the laser therapy plus exercise group pain had reduced by 1.8 cm (95% CI 0.1 to 3.3,  $p = 0.03$ ), lumbar range of movement increased by 0.9 cm (95% CI 0.2 to 1.8,  $p < 0.01$ ) on the Schober Test and by 15 deg (95% CI 5 to 25,  $p < 0.01$ ) of active flexion, and disability reduced by 9.4 points (95% CI 2.7 to 16.0,  $p = 0.03$ ) more than in the exercise group at 12 weeks. Conclusion: In chronic low back pain low level laser therapy combined with exercise is more beneficial than exercise alone in the long term.

PMID: 17725472 [PubMed - in process]

- 1: [Photomed Laser Surg.](#) 2007 Oct;25(5):436-42. Mary Ann Liebert, [Links](#)

## **Laser phototherapy (780 nm), a new modality in treatment of long-term incomplete peripheral nerve injury: a randomized double-blind placebo-controlled study.**

[Rochkind S](#), [Drory V](#), [Alon M](#), [Nissan M](#), [Ouaknine GE](#).

Division of Peripheral Nerve Reconstruction, Department of Neurosurgery, Tel Aviv Sourasky Medical Center, Tel Aviv University, Israel. rochkind@zahav.net.il

**OBJECTIVE:** The authors conducted this pilot study to prospectively investigate the effectiveness of low-power laser irradiation (780 nm) in the treatment of patients suffering from incomplete peripheral nerve and brachial plexus injuries for 6 months up to several years. **BACKGROUND DATA:** Injury of a major nerve trunk frequently results in considerable disability associated with loss of sensory and motor functions. Spontaneous recovery of long-term severe incomplete peripheral nerve injury is often unsatisfactory. **METHODS:** A randomized, double-blind, placebo-controlled trial was performed on 18 patients who were randomly assigned placebo (non-active light: diffused LED lamp) or low-power laser irradiation (wavelength, 780 nm; power, 250 mW). Twenty-one consecutive daily sessions of laser or placebo irradiation were applied transcutaneously for 3 h to the injured peripheral nerve (energy density, 450 J/mm<sup>2</sup>) and for 2 h to the corresponding segments of the spinal cord (energy density, 300 J/mm<sup>2</sup>). Clinical and electrophysiological assessments were done at baseline, at the end of the 21 days of treatment, and 3 and 6 months thereafter. **RESULTS:** The laser-irradiated and placebo groups were in clinically similar conditions at baseline. The analysis of motor function during the 6-month follow-up period compared to baseline showed statistically significant improvement ( $p = 0.0001$ ) in the laser-treated group compared to the placebo group. No statistically significant difference was found in sensory function. Electrophysiological analysis also showed statistically significant improvement in recruitment of voluntary muscle activity in the laser-irradiated group ( $p = 0.006$ ), compared to the placebo group. **CONCLUSION:** This pilot study suggests that in patients with long-term peripheral nerve injury noninvasive 780-nm laser phototherapy can progressively improve nerve function, which leads to significant functional recovery.

PMID: 17975958 [PubMed - in process]

□ 1: [Photomed Laser Surg.](#) 2007 Feb;25(1):34-9.  [Links](#)

## Laser therapy in the treatment of carpal tunnel syndrome: a randomized controlled trial.

[Evcik D](#), [Kavuncu V](#), [Cakir T](#), [Subasi V](#), [Yaman M](#).

Department of Physical Rehabilitation Medicine, Kocatepe University, Afyonkarahisar, Turkey.  
evcikd@yahoo.com

**OBJECTIVE:** This prospective, randomized, placebo-controlled trial aimed to investigate the efficacy of laser therapy in the treatment of carpal tunnel syndrome (CTS). **BACKGROUND DATA:** Low-level laser therapy (LLLT) has been found to have positive effects in the treatment of CTS and various musculoskeletal conditions. **METHODS:** A total of 81 patients were included in this study. Diagnosis of CTS was based on both clinical examination and electromyographic (EMG) study. Patients were randomly assigned into two groups. Group 1 (n = 41) underwent laser therapy (7 joules/2 min) over the carpal tunnel area. Group 2 (n = 40) received placebo laser therapy. All patients received therapy five times per week, for a total of 10 sessions. Patients also used a wrist splint each night. Patients were assessed according to pain, hand-pinch grip strength, and functional capacity. Pain was evaluated by Visual Analog Scale (VAS; day-night). Hand grip was measured by Jamar dynamometer, and pinch grip was measured by pinchmeter. Functional capacity was assessed by a self-administered questionnaire for severity of symptoms. **RESULTS:** The mean age of the patients (70 women, 11 Men) was 49.3 +/- 11.0 (range, 26-78). After therapy there were statistically significant improvements in VAS, pinch grip, and functional capacity measurement in both groups (p < 0.001). Hand grip was found to have been improved in the laser group. In EMG, there were statistically improvements in sensory nerve velocity, and sensory and motor distal latencies in the laser group (p < 0.001). Only sensory nerve velocity was meaningful in the placebo group. **CONCLUSION:** In using LLLT, (1) there was no difference relative to pain relief and functional capacity during the follow-up in CTS patients; (2) there were positive effects on hand and pinch grip strengths.

PMID: 17352635 [PubMed - indexed for MEDLINE]

1: [Swiss Med Wkly](#). 2007 Jun 16;137(23-24):347-52.



[Links](#)

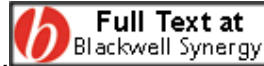## Effect of low level laser therapy in rheumatoid arthritis patients with carpal tunnel syndrome.

[Ekim A](#), [Armagan O](#), [Tascioglu F](#), [Oner C](#), [Colak M](#).

Osmangazi University, Department of Physical Therapy and Rehabilitation, Eskisehir, Turkey.

**OBJECTIVE:** the aim of the present study was to evaluate the efficacy of low level laser therapy (LLLT) in patients with rheumatoid arthritis (RA) with carpal tunnel syndrome (CTS). **MATERIAL AND METHODS:** a total of 19 patients with the diagnosis of CTS in 19 hands were included and randomly assigned to two treatment groups; LLLT (Group 1) (10 hands) with dosage 1.5 J/ per point and placebo laser therapy group (Group 2) (9 hands). A Gallium-Aluminum-Arsenide diode laser device was used as a source of low power laser with a power output of 50 mW and wavelength of 780 nm. All treatments were applied once a day on week days for a total period of 10 days. Clinical assessments were performed at baseline, at the end of the treatment and at month 3. Tinel and Phalen signs were tested in all patients. Patients were evaluated for such clinical parameters as functional status scale (FSS), visual analogue scale (VAS), symptom severity scale (SSS) and grip-strength. However, electrophysiological examination was performed on all hands. Results were given with descriptive statistics and confidence intervals between group means at 3 months adjusted for outcome at baseline and for the difference between unadjusted group proportions. **RESULTS:** clinical and electrophysiological parameters were similar at baseline in both groups. Improvements were significantly more pronounced in the LLLT group than placebo group. A comparison between groups showed significant improvements in pain score and functional status scale score. Group mean differences at 3 months adjusted at baseline were found to be statistically significant for pain score and functional status scale score. The 95% significant confidence intervals were [-15 - (-5)] and [-5 - (-2)] respectively. There were no statistically significant differences in other clinical and electrophysiological parameters between groups at 3 months. **CONCLUSIONS:** our study results indicate that LLLT and placebo laser therapy seems to be effective for pain and hand function in CTS. We, therefore, suggest that LLLT may be used as a good alternative treatment method in CTS patients with RA.

PMID: 17629805 [PubMed - indexed for MEDLINE]



1: [Br J Dermatol.](#) 2006 Oct;155(4):748-55.

[Links](#)

Erratum in:

Br J Dermatol. 2007 Feb;156(2):409. Seldon, P E [corrected to Seldon, P M].

## **Investigation of the mechanism of action of nonablative pulsed-dye laser therapy in photorejuvenation and inflammatory acne vulgaris.**

[Seaton ED](#), [Mouser PE](#), [Charakida A](#), [Alam S](#), [Seldon PM](#), [Chu AC](#).

Department of Dermatology, Hammersmith Hospital, Imperial College, London W12 0NN, UK.  
edwardseaton@hotmail.co.uk

**BACKGROUND:** Nonablative lasers are widely used for treatment of wrinkles, atrophic scars and acne. These lasers stimulate dermal remodelling and collagen production, but the early molecular stimulus for this is unknown. The mechanism of nonablative lasers in inflammatory acne is variously suggested to be damage either to sebaceous glands or to Propionibacterium acnes. Their effects on cytokine production are unknown. **OBJECTIVES:** To assess the in vivo effects of a short pulse duration nonablative pulsed-dye laser (NA-PDL) previously used for photorejuvenation and treatment of acne, on cytokine production, P. acnes colonization density and sebum excretion rate (SER). **METHODS:** We examined the effect of NA-PDL (NliteV; Chromogenex Light Technologies, Llanelli, U.K.) on P. acnes colonization before and after laser therapy using a scrub-wash technique and culture at 0 and 24 h (n = 15), on SER using absorptive tape at 0, 2, 4, 8 and 12 weeks (n = 19) and on cytokine mRNA using reverse transcription-polymerase chain reaction from skin biopsies at 0, 3 and 24 h (n = 8). **RESULTS** NA-PDL had no effect on P. acnes or SER. Transforming growth factor (TGF)-beta1 mRNA increased fivefold after 24 h and 15-fold in two subjects (P = 0.012). **CONCLUSIONS:** TGF-beta is known to be a potent stimulus for neocollagenesis and a pivotal immunosuppressive cytokine which promotes inflammation resolution. Its upregulation by NA-PDL provides a possible unifying molecular mechanism linking stimulation of dermal remodelling in photorejuvenation with inhibition of inflammation in acne. Damage to P. acnes or sebaceous glands cannot explain the effect of this device in acne.

PMID: 16965424 [PubMed - indexed for MEDLINE]

□ 1: [Pain](#). 2007 Nov 15 [Epub ahead of print]  [Links](#)


## Laser acupuncture in children with headache: A double-blind, randomized, bicenter, placebo-controlled trial.

[Gottschling S](#), [Meyer S](#), [Gribova I](#), [Distler L](#), [Berrang J](#), [Gortner L](#), [Graf N](#), [Shamdeen MG](#).

University Children's Hospital, Department of Pediatric Hematology and Oncology, Saarland University, Kirrbergerstr., 66421 Homburg, Germany.

To investigate whether laser acupuncture is efficacious in children with headache and if active laser treatment is superior to placebo laser treatment in a prospective, randomized, double-blind, placebo-controlled trial of low level laser acupuncture in 43 children (mean age (SD) 12.3 (+/-2.6) years) with headache (either migraine (22 patients) or tension type headache (21 patients)). Patients were randomized to receive a course of 4 treatments over 4 weeks with either active or placebo laser. The treatment was highly individualised based on criteria of Traditional Chinese medicine (TCM). The primary outcome measure was a difference in numbers of headache days between baseline and the 4 months after randomization. Secondary outcome measures included a change in headache severity using a 10cm Visual Analogue Scale (VAS) for pain and a change in monthly hours with headache. Measurements were taken during 4 weeks before randomization (baseline), at weeks 1-4, 5-8, 9-12 and 13-16 from baseline. The mean number of headaches per month decreased significantly by 6.4 days in the treated group ( $p < 0.001$ ) and by 1.0 days in the placebo group ( $p = 0.22$ ). Secondary outcome measures headache severity and monthly hours with headache decreased as well significantly at all time points compared to baseline ( $p < 0.001$ ) and were as well significantly lower than those of the placebo group at all time points ( $p < 0.001$ ). We conclude that laser acupuncture can provide a significant benefit for children with headache with active laser treatment being clearly more effective than placebo laser treatment.

PMID: 18022318 [PubMed - as supplied by publisher]

- 1: [Photomed Laser Surg.](#) 2007 Feb;25(1):14-20.  [Links](#)

**Laser acupuncture in knee osteoarthritis: a double-blind, randomized controlled study.**

[Yurtkuran M](#), [Alp A](#), [Konur S](#), [Ozçakir S](#), [Bingol U](#).

Division of Rheumatology, Uludag University Atatürk Rehabilitation Center, Bursa, Turkey.  
merihcan@hotmail.com

**OBJECTIVE:** The purpose of this study was to investigate the effects and minimum effective dose of laser acupuncture in knee osteoarthritis (KOA), and to determine if it is superior to placebo treatment (sham) in the evaluation of clinical-functional outcome and quality of life. **METHODS:** In this randomized, placebo-controlled study, patients with grade 2 and 3 primary KOA were selected. Group I (n = 27) received 904-nm low-level laser irradiation with 10 mW/cm<sup>2</sup> power density, 4 mW output power, 0.4 cm<sup>2</sup> spot size, 0.48 J dose per session, and 120-sec treatment time on the medial side of the knee to the acupuncture point Sp9. Group II (n = 25) received placebo-laser therapy at the same place on the same point. Patients in both of the groups had treatment 5 days per week (total duration of therapy was 10 days) and 20 min per day. The study was comprised of a 2-week (10-session) intervention. Participants were evaluated before treatment (baseline), after treatment (2nd week), and at the 12th week. In this double-blind study, a blind examiner carried out all outcome assessments. The main outcome measures were as follows: pain on movement (pVAS), 50-foot walking time (50 foot w), knee circumference (KC), medial tenderness score (MTS), Western Ontario and McMaster Universities osteoarthritis index (WOMAC), and Nottingham Health Profile (NHP). **RESULTS:** Statistically significant improvement was observed in pVAS, 50 foot w, and KC in group 1. In Group II, statistically significant improvement was observed in pVAS, 50 foot w, and WOMAC. When groups were compared with each other, the improvement observed in KC was superior in Group I at the 2(nd) week (p = 0.005). **CONCLUSION:** Laser acupuncture was found to be effective only in reducing periarticular swelling when compared with placebo laser.

PMID: 17352632 [PubMed - indexed for MEDLINE]

Signifikans bara på ödem.

- ✓ 1: [Cranio](#). 2007 Jul;25(3):186-92. [Links](#)


## **Low intensity laser application in temporomandibular disorders: a phase I double-blind study.**

[Mazzetto MO](#), [Carrasco TG](#), [Bidinelo EF](#), [de Andrade Pizzo RC](#), [Mazzetto RG](#).

Department of Restorative Dentistry, School of Dentistry of Ribeirão Preto, University of São Paulo (FORP-USP), Brazil. [mazzetto@forp.usp.br](mailto:mazzetto@forp.usp.br)

The purpose of this study was to evaluate the effectiveness of low intensity laser therapy (LILT) for the control of pain from temporomandibular disorder (TMD) in a random and double-blind research design. Forty-eight (48) patients presenting temporomandibular joint (TMJ) pain were divided into an experimental group (GI) and a placebo group (GII). The sample was submitted to the treatment with infrared laser (780 nm, 70 mW, 10 s, 89.7 J/cm<sup>2</sup>) applied in continuous mode on the affected temporomandibular region, at one point: inside the external auditive duct toward the retrodiskal region, twice a week, for four weeks. For the control group, two identical probes (one active and one that does not emit radiation) were used unknown by the clinician and the subjects. A tip planned for laser acupuncture was used and connected to the active point of the probe. The parameter evaluated was the intensity of pain after palpation of the condylar lateral pole, pre-auricular region and external auditive duct, according to the Visual Analogue Scale (VAS). Four evaluations were performed: Ev1 (before laser application), Ev2 (after 4th application), Ev3 (after 8th application) and Ev4 (30 days after the last application). Data were submitted to statistical analysis. The results showed a decrease in the pain level mainly for the active probe. Among the evaluations, the Ev3 exhibited lower sensitivity to palpation. In conclusion, the results show that low intensity laser is an effective therapy for the pain control of subjects with TMD.

PMID: 17696035 [PubMed - in process]

1: [Photomed Laser Surg.](#) 2007 Aug;25(4):297-303.  [Links](#)

## Effectiveness of low-level laser therapy in temporomandibular joint disorders: a placebo-controlled study.

[Fikácková H](#), [Dostálová T](#), [Navrátil L](#), [Klaschka J](#).

Institute of Biophysics and Informatics, 1st Medical Faculty, Charles University, Prague, Czech Republic.

**OBJECTIVE:** Low-level laser therapy (LLLT) treatment for pain caused by temporomandibular joint disorders (TMD) was investigated in a controlled study comparing applied energy density, subgroups of TMD, and duration of disorders. **BACKGROUND DATA:** Although LLLT is a physical therapy used in the treatment of musculoskeletal disorders, there is little evidence for its effectiveness in the treatment of TMD. **METHODS:** The study group of 61 patients was treated with 10 J/cm<sup>2</sup> or 15 J/cm<sup>2</sup>, and the control group of 19 patients was treated with 0.1 J/cm<sup>2</sup>. LLLT was performed by a GaAlAs diode laser with output of 400 mW emitting radiation wavelength of 830 nm in 10 sessions. The probe with aperture 0.2 cm<sup>2</sup> was placed over the painful muscle spots in the patients with myofascial pain. In patients with TMD arthralgia the probe was placed behind, in front of, and above the mandibular condyle, and into the meatus acusticus externus. Changes in pain were evaluated by self-administered questionnaire.

**RESULTS:** Application of 10 J/cm<sup>2</sup> or 15 J/cm<sup>2</sup> was significantly more effective in reducing pain compared to placebo, but there were no significant differences between the energy densities used in the study group and between patients with myofascial pain and temporomandibular joint arthralgia. Results were marked in those with chronic pain. **CONCLUSION:** The results suggest that LLLT (application of 10 J/cm<sup>2</sup> and 15 J/cm<sup>2</sup>) can be considered as a useful method for the treatment of TMD-related pain, especially long lasting pain.

PMID: 17803388 [PubMed - indexed for MEDLINE]

□ 1: [Support Care Cancer](#). 2007 Oct;15(10):1145-54. Epub 2007 Mar

29.  [FULL-TEXT ARTICLE](#) [Links](#)

## **A phase III randomized double-blind placebo-controlled clinical trial to determine the efficacy of low level laser therapy for the prevention of oral mucositis in patients undergoing hematopoietic cell transplantation.**

[Schubert MM](#), [Eduardo FP](#), [Guthrie KA](#), [Franquin JC](#), [Bensadoun RJ](#), [Migliorati CA](#), [Lloid CM](#), [Eduardo CP](#), [Walter NF](#), [Marques MM](#), [Hamdi M](#).

Department of Oral Medicine, Seattle Cancer Care Alliance, University of Washington, 825 Eastlake Ave E, Seattle, WA, 98109, USA.

**INTRODUCTION:** Oral mucositis (OM) is a significant early complication of hematopoietic cell transplantation (HCT). This phase III randomized double-blind placebo-controlled study was designed to compare the ability of 2 different low level GaAlAs diode lasers (650 nm and 780 nm) to prevent oral mucositis in HCT patients conditioned with chemotherapy or chemoradiotherapy. **MATERIALS AND METHODS:** Seventy patients were enrolled and randomized into 1 of 3 treatment groups: 650 nm laser, 780 nm laser or placebo. All active laser treatment patients received daily direct laser treatment to the lower labial mucosa, right and left buccal mucosa, lateral and ventral surfaces of the tongue, and floor of mouth with energy densities of 2 J/cm<sup>2</sup>. Study treatment began on the first day of conditioning and continued through day +2 post HCT. Mucositis and oral pain was measured on days 0, 4, 7, 11, 14, 18, and 21 post HCT. **RESULTS:** The 650 nm wavelength reduced the severity of oral mucositis and pain scores. Low level laser therapy was well-tolerated and no adverse events were noted. **DISCUSSION:** While these results are encouraging, further study is needed to truly establish the efficacy of this mucositis prevention strategy. Future research needs to determine the effects of modification of laser parameters (e.g., wavelength, fluence, repetition rate of energy delivery, etc.) on the effectiveness of LLE laser to prevent OM.

PMID: 17393191 [PubMed - in process]

- 1: [J Laryngol Otol.](#) 2007 Jul 12;:1-5 [Epub ahead of print] [Links](#)

## **Effectiveness of transmeatal low power laser irradiation for chronic tinnitus.**

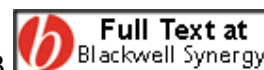[Gungor A](#), [Dogru S](#), [Cincik H](#), [Erkul E](#), [Poyrazoglu E](#).

Department of Otolaryngology, Haydarpasa Military Hospital, Istanbul, Turkey.

Objective: To evaluate effectiveness of 5 mW laser irradiation in the treatment of chronic tinnitus. Study design: Prospective, randomised, double-blind study. Methods: This investigation included 66 ears in 45 patients with chronic unilateral or bilateral tinnitus. A 5 mW laser with a wavelength of 650 nm, or placebo laser, was applied transmeatally for 15 minutes, once daily for a week. A questionnaire was administered which asked patients to score their symptoms on a five-point scale, before and two weeks after laser irradiation. A decrease of one scale point, regarding the loudness, duration and degree of annoyance of tinnitus, was accepted to represent an improvement. Results: The loudness, duration and degree of annoyance of tinnitus were improved, respectively, in up to 48.8, 57.7 and 55.5 per cent of the patients in the active laser group. No significant improvement was observed in the placebo laser group. Conclusion: Transmeatal, low power (5 mW) laser irradiation was found to be useful for the treatment of chronic tinnitus.

PMID: 17625032 [PubMed - as supplied by publisher]

1: [J Clin Periodontol](#). 2008 Feb;35(2):147-56. Epub 2007 Dec 13.



[Links](#)

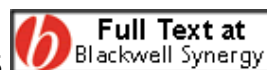## Enamel matrix derivative and low-level laser therapy in the treatment of intra-bony defects: a randomized placebo-controlled clinical trial.

[Ozcelik O](#), [Cenk Haytac M](#), [Seydaoglu G](#).

Department of Periodontology, Faculty of Dentistry, Cukurova University, Adana, Turkey.

**Aim:** The aim of this study was to evaluate the immediate post-operative pain, wound healing and clinical results after the application of an enamel matrix protein derivative (EMD) alone or combined with a low-level laser therapy (LLLT) for the treatment of deep intra-bony defects. **Material and Methods:** This study was an intra-individual longitudinal test of 12 months' duration conducted using a blinded, split-mouth, placebo-controlled and randomized design. In 22 periodontitis patients, one intra-bony defect was randomly treated with EMD+LLLT, while EMD alone was applied to the contra-lateral defect site. LLLT was used both intra- and post-operatively. Clinical measurements were performed by a blinded periodontist at the time of surgery, in the first week and in the first, second, sixth and 12th month. Visual analogue scale (VAS) scores were recorded for pain assesment. **Results:** The results have shown that the treatment of intra-bony defects with EMD alone or EMD+LLLT leads to probing depth reduction and attachment-level gain. In addition, EMD+LLLT had resulted in less gingival recession ( $p<0.05$ ), less swelling ( $p<0.001$ ) and less VAS scores ( $p<0.02$ ) compared with EMD alone. **Conclusion:** This study shows that EMD is an effective, safe and predictable biomaterial for periodontal regeneration and LLLT may improve the effects of EMD by reducing post-operative complications.

1: [Dermatol Surg.](#) 2008 Jan;34(1):67-72. Epub 2007 Dec 5.



[Links](#)

## **Pulsed dye laser treatment is effective in the treatment of recalcitrant viral warts.**

[Schellhaas U](#), [Gerber W](#), [Hammes S](#), [Ockenfels HM](#).

Department of Dermatology and Allergy, Klinikum Stadt Hanau, Hanau, Germany.

**BACKGROUND:** Verrucae vulgaris can be removed in a variety of ways but a specific therapy of choice has not yet been developed. Doctors are faced with a challenge, especially in the treatment of recalcitrant warts. It has been suggested that the success of pulsed dye laser treatment lies in the fact that warts contain an increased number of dilated blood vessels. **METHODS:** Seventy-three patients (42 female, 31 male) with verrucae vulgaris on their hands or feet (1:1.5) were given a maximum of 12 treatments with a flashlamp-pumped pulsed dye laser every 2 weeks over a period of 24 weeks until complete clearance had been achieved. A laser energy density of 8 to 12 J/cm<sup>2</sup> with a spot size of 5 mm and a pulse duration of 450 microsec were used. The minimum follow-up period was 6 months. **RESULTS:** A total of 15.1% patients achieved complete clearance after 1 session and 47.9% after 2 to 5 sessions, resulting in a remission of 63.0% patients after a maximum of 5 treatment sessions. A remission of 23.3% patients was seen after 6 to 9 treatments and a total of 89.0% of patients showed remission after a maximum of 10 sessions. Only three patients (4.1%) failed and five patients (6.9%) stopped the treatment on account of pain/noncompliance. Only one patient, from a group of patients treated between January 2003 and April 2004, has relapsed. **CONCLUSION:** Pulsed dye laser treatment is effective and safe in the treatment of recalcitrant viral warts.

PMID: 18053048 [PubMed - indexed for MEDLINE]

# Exempel på djurstudier under 2007

Från [www.pubmed.com](http://www.pubmed.com) / sökord laser therapy

1: [J Photochem Photobiol B](#). 2007 Nov 12;89(1):50-5. Epub 2007 Sep

ELSEVIER  
6. FULL-TEXT ARTICLE

[Links](#)


## Anti-inflammatory effects of low-level laser therapy (LLLT) with two different red wavelengths (660nm and 684nm) in carrageenan-induced rat paw edema.

[Albertini R](#), [Villaverde AB](#), [Aimbire F](#), [Salgado MA](#), [Bjordal JM](#), [Alves LP](#), [Munin E](#), [Costa MS](#).

Instituto de Pesquisa & Desenvolvimento - IP&D, Universidade do Vale do Paraíba - UNIVAP, Av. Shishima Hifumi, 2911, CEP: 12244-000 São José dos Campos, SP, Brazil.

It has been suggested that low-level laser therapy (LLLT) can modulate inflammatory processes. The aim of this experiment was to investigate what effects red laser irradiation with two different wavelengths (660nm and 684nm) on carrageenan-induced rat paw edema and histology. Thirty two male Wistar rats were randomly divided into four groups. One group received a sterile saline injection, while inflammation was induced by a sub-plantar injection of carrageenan (1mg/paw) in the three other groups. After 1h, LLLT was administered to the paw in two of the carrageenan-injected groups. Continuous wave 660nm and 684nm red lasers respectively with mean optical outputs of 30mW and doses of 7.5J/cm<sup>2</sup> were used. The 660nm and 684nm laser groups developed significantly ( $p < 0.01$ ) less edema (0.58ml [SE $\pm$ 0.17] ml and 0.76ml [SE $\pm$ 0.10] respectively) than the control group (1.67ml [SE $\pm$ 0.19]) at 4h after injections. Similarly, both laser groups showed a significantly lower number of inflammatory cells in the muscular and conjunctive sub-plantar tissues than the control group. We conclude that both 660nm and 684nm red wavelengths of LLLT are effective in reducing edema formation and inflammatory cell migration when a dose of 7.5J/cm<sup>2</sup> is used.

PMID: 17920925 [PubMed - in process]

1: [Inflamm Res.](#) 2007 Jun;56(6):228-9.  [Links](#)


## COX-2 mRNA expression decreases in the subplantar muscle of rat paw subjected to carrageenan-induced inflammation after low level laser therapy.

[Albertini R](#), [Aimbire F](#), [Villaverde AB](#), [Silva JA Jr](#), [Costa MS](#).

IP&D - UNIVAP, Av, Shishima Hifumi 2911, CEP: 12244-000, São José dos Campos, Brazil, mscosta@univap.br.

OBJECTIVE AND DESIGN: Low level laser therapy (LLLT) has been presented as a novel therapy to treat inflammation. Herein we studied the effect of LLLT on the COX-2 mRNA expression in subplantar tissue taken from rats treated with carrageenan. MATERIAL: The groups consisted of 32 rats: A (1) (Saline), A (2) (Carrageenan), A (3) (Carrageenan + laser 660 nm) and A (4) (Carrageenan + laser 684 nm). TREATMENT: A (3) and A (4) were irradiated in the first hour after carrageenan. METHODS: The edema was measured by a plethysmometer and COX-2 mRNA was by RT-PCR. Statistical were evaluated by ANOVA and Tukey-Kramer Test. RESULTS: Carrageenan increased both edema (A (1)= 0.6 +/- 0.04 vs. A (2)= 2.24 +/- 0.08) and COX-2 mRNA (A (1)= 1.1 +/- 0.26 vs. A (2)= 3.52 +/- 0.69). Irradiation reduced the edema (A (3)= 0.84 +/- 0.09; A4= 1.31 +/- 0.05) and the COX-2 mRNA (A (3)= 2.16 +/- 0.28; A (4)= 1.86 +/- 0.20). CONCLUSION: LLLT reduce the expression of COX-2 mRNA.

PMID: 17607546 [PubMed - in process]

□ 1: [Braz J Med Biol Res.](#) 2007 Jun;40(6):877-84.  [Links](#)

## Influence of He-Ne laser therapy on the dynamics of wound healing in mice treated with anti-inflammatory drugs.

[Gonçalves WL](#), [Souza FM](#), [Conti CL](#), [Cirqueira JP](#), [Rocha WA](#), [Pires JG](#), [Barros LA](#), [Moysés MR](#).

Departamento de Ciências Fisiológicas, Centro de Ciências da Saúde, Universidade Federal do Espírito Santo.

We determined the effects of helium-neon (He-Ne) laser irradiation on wound healing dynamics in mice treated with steroidal and non-steroidal anti-inflammatory agents. Male albino mice, 28-32 g, were randomized into 6 groups of 6 animals each: control (C), He-Ne laser (L), dexamethasone (D), D + L, celecoxib (X), and X + L. D and X were injected im at doses of 5 and 22 mg/kg, respectively, 24 h before the experiment. A 1-cm long surgical wound was made with a scalpel on the abdomens of the mice. Animals from groups L, D + L and X + L were exposed to 4 J (cm<sup>2</sup>)-1 day-1 of He-Ne laser for 12 s and were sacrificed on days 1, 2, or 3 after the procedure, when skin samples were taken for histological examination. A significant increase of collagen synthesis was observed in group L

compared with C (168 +/- 20 vs 63 +/- 8 mm(2)). The basal cellularity values on day 1 were: C = 763 +/- 47, L = 1116 +/- 85, D = 376 +/- 24, D + L = 698 +/- 31, X = 453 +/- 29, X + L = 639 +/- 32 U/mm(2). These data show that application of L increases while D and X decrease the inflammatory cellularity compared with C. They also show that L restores the diminished cellularity induced by the anti-inflammatory drugs. We suggest that He-Ne laser promotes collagen formation and restores the baseline cellularity after pharmacological inhibition, indicating new perspectives for laser therapy aiming to increase the healing process when anti-inflammatory drugs are used.

PMID: 17581688 [PubMed - in process]

1: [Lasers Surg Med.](#) 2007 Dec;39(10):797-802.



[Links](#)

## **GaAIAs (830 nm) low-level laser enhances peripheral endogenous opioid analgesia in rats.**

[Hagiwara S](#), [Iwasaka H](#), [Okuda K](#), [Noguchi T](#).

Department of Brain and Nerve Science, Anesthesiology, Oita University Faculty of Medicine, 1-1 Idaigaoka-Hasamamachi-Yufu City-Oita 879-5593, Japan.

**BACKGROUND:** Low-level laser therapy (LLLT) has been reported to relieve pain with minimal side effects. Recent studies have demonstrated that opioid-containing immune cells migrate to inflamed sites and release beta-endorphins to inhibit pain as a mode of peripheral endogenous opioid analgesia. The present study investigates whether LLLT may enhance peripheral endogenous opioid analgesia.

**METHODS:** The effect of LLLT on opioid analgesia and production was evaluated in vivo in a rat model of inflammation as well as in vitro in Jurkat cells, a human T-cell leukemia cell line. mRNA expression of the beta-endorphin precursors proopiomelanocortin and corticotrophin releasing factor was assessed by reverse transcription polymerase chain reaction. **RESULTS:** LLLT produced an analgesic effect in inflamed peripheral tissue which was transiently antagonized by naloxone. Beta-endorphin precursor mRNA expression increased with LLLT, both in vivo and in vitro. **CONCLUSION:** This study demonstrates that LLLT produces analgesic effects in a rat model of peripheral inflammation. We further revealed an additional mechanism of LLLT-mediated analgesia via enhancement of peripheral endogenous opioids. These findings suggest that LLLT induces analgesia in rats by enhancing peripheral endogenous opioid production in addition to previously reported mechanisms. *Lasers Surg. Med.* 39:797-802, 2007. (c) 2007 Wiley-Liss, Inc.

PMID: 18081143 [PubMed - in process]

*Photomed Laser Surg.* 2007 Feb;25(1):63. Piccolo, G [corrected to Picolo, G].

## **Analgesic effect of He-Ne (632.8 nm) low-level laser therapy on acute inflammatory pain.**

[Ferreira DM](#), [Zângaro RA](#), [Villaverde AB](#), [Cury Y](#), [Frigo L](#), [Picolo G](#), [Longo J](#), [Barbosa DG](#).

Instituto de Pesquisa e Desenvolvimento, Universidade do Vale do Paraíba, São José dos Campos, São Paulo, SP, Brazil.

**OBJECTIVE:** The aim of this study was to evaluate the analgesic effect of the low level laser therapy (LLLT) with a He-Ne laser on acute inflammatory pain, verifying the contribution of the peripheral opioid receptors and the action of LLLT on the hyperalgesia produced by the release of hyperalgesic mediators of inflammation. **BACKGROUND DATA:** All analgesic drugs have undesired effects. Because of that, other therapies are being investigated for treatment of the inflammatory pain. Among those, LLLT seems to be very promising.

20

Internationellt momsnummer: SE556196619201.

Postgiro nr: 14723 - 1. **Bankgiro: 795-0504.**

**IRRADIA AB**, Box 27137, 102 52 Stockholm, Sweden  
Besöksadress: Norra Hamnvägen 3-5, 115 42 Stockholm, Sweden  
E-mail: laser@irradia.se

Telefon: 08-7672700 (-01, -03). Telefax: 08-7672706  
Bank: SE-Banken, Lidingö  
Hemsida: www.irradia.se

**MATERIAL AND METHODS:** Male Wistar rats were used. Three complementary experiments were done. (1) The inflammatory reaction was induced by the injection of carrageenin into one of the hind paws. Pain threshold and volume increase of the edema were measured by a pressure gauge and plethysmography, respectively. (2) The involvement of peripheral opioid receptors on the analgesic effect of the laser was evaluated by simultaneous injection of carrageenin and naloxone into one hind paw. (3) Hyperalgesia was induced by injecting PGE2 for the study of the effect of the laser on the sensitization increase of nociceptors. A He-Ne laser (632.8 nm) of 2.5 J/cm<sup>2</sup> was used for irradiation. **RESULTS:** We found that He-Ne stimulation increased the pain threshold by a factor between 68% and 95% depending on the injected drug. We also observed a 54% reduction on the volume increase of the edema when it was irradiated. **CONCLUSION:** He-Ne LLLT inhibits the sensitization increase of nociceptors on the inflammatory process. The analgesic effect seems to involve hyperalgesic mediators instead of peripheral opioid receptors.

1: [Lasers Surg Med.](#) 2007 Jul;39(6):543-50.



[Links](#)

## **Low-level laser therapy for zymosan-induced arthritis in rats: Importance of illumination time.**

[Castano AP](#), [Dai T](#), [Yaroslavsky I](#), [Cohen R](#), [Apruzzese WA](#), [Smotrich MH](#), [Hamblin MR](#).

Wellman Center for Photomedicine, Massachusetts General Hospital, Boston, Massachusetts 02114, USA.

**BACKGROUND:** It has been proposed for many years that low-level laser (or light) therapy (LLLT) can ameliorate the pain, swelling, and inflammation associated with various forms of arthritis. Light is thought to be absorbed by mitochondrial chromophores leading to an increase in adenosine triphosphate (ATP), reactive oxygen species and/or cyclic AMP production and consequent gene transcription via activation of transcription factors. However, despite many reports about the positive effects of LLLT in arthritis and in medicine in general, its use remains controversial. For all indications (including arthritis) the optimum optical parameters have been difficult to establish and so far are unknown. **METHODS:** We tested LLLT on rats that had zymosan injected into their knee joints to induce inflammatory arthritis. We compared illumination regimens consisting of a high and low fluence (3 and 30 J/cm<sup>2</sup>), delivered at high and low irradiance (5 and 50 mW/cm<sup>2</sup>) using 810-nm laser light daily for 5 days, with the positive control of conventional corticosteroid (dexamethasone) therapy. **RESULTS:** Illumination with 810-nm laser was highly effective (almost as good as dexamethasone) at reducing swelling and a longer illumination time (10 or 100 minutes compared to 1 minute) was more important in determining effectiveness than either the total fluence delivered or the irradiance. LLLT induced reduction of joint swelling correlated with reduction in the inflammatory marker serum prostaglandin E<sub>2</sub> (PGE<sub>2</sub>). **CONCLUSION:** **LLLT with 810-nm laser is highly effective in treating inflammatory arthritis in this model. Longer illumination times were more effective than short times regardless of total fluence or irradiance. These data will be of value in designing clinical trials of LLLT for various arthritides.** (c) 2007 Wiley-Liss, Inc.

- 1: [Lasers Surg Med.](#) 2007 Jun;39(5):428-40.



[Links](#)

## **Immunohistochemical characterization of periodontal wound healing following nonsurgical treatment with fluorescence controlled Er:YAG laser radiation in dogs.**

[Schwarz F](#), [Jepsen S](#), [Herten M](#), [Aoki A](#), [Sculean A](#), [Becker J](#).

Department of Oral Surgery, Heinrich Heine University, D-40225 Düsseldorf, Germany.  
info@frank-schwarz.de

BACKGROUND AND OBJECTIVE: The aim of the present study was to immunohistochemically characterize periodontal wound healing following nonsurgical treatment with fluorescence controlled Er:YAG laser radiation in dogs. STUDY DESIGN/MATERIALS AND METHODS: Five beagle dogs suffering from naturally occurring chronic periodontitis were randomly allocated in a split-mouth design to nonsurgical periodontal treatment using either (a) an Er:YAG laser at 10.2, 12.8, 15.4, 18, and 20.4 J/cm<sup>2</sup> (ERL1-5), or (b) an ultrasonic device (VUS) serving as control. The animals were sacrificed after 3 months. Histomorphometrical (e.g. inflammatory cell infiltrate, surface changes, cementum formation), and immunohistochemical parameters (collagen type I, CD68, matrix metalloproteinase (MMP)-8) were assessed. RESULTS: Inflammatory cell infiltrates of different extent were commonly observed in all treatment groups. However, histomorphometrical analysis revealed new cementum formation with inserting collagen type I fibers along the instrumented root surfaces in most specimens of both ERL (ERL2: 31+/-81 to ERL5: 595+/-575 microm) and VUS (50+/- 215 microm) groups. This was associated with pronounced CD68 and weak MMP-8 antigen reactivity. CONCLUSION: Within the limits of the present study, it was concluded that both treatment procedures (i) were effective in controlling inflammatory cell infiltrates, and (ii) may support the formation of a new connective tissue attachment. (c) 2007 Wiley-Liss, Inc.

PMID: 17523168 [PubMed - in process]

- 1: [Photomed Laser Surg.](#) 2007 Apr;25(2):112-7.



[Links](#)

## **Effect of low-level laser therapy on hemorrhagic lesions induced by immune complex in rat lungs.**

[Aimbire F](#), [Lopes-Martins RA](#), [Albertini R](#), [Pacheco MT](#), [Castro-Faria-Neto HC](#), [Martins PS](#), [Bjordial JM](#).

Laboratory of Animal Experimentation, Research and Development Institute

22

**OBJECTIVE:** The aim of this study was to investigate if low-level laser therapy (LLLT) can modulate formation of hemorrhagic lesions induced by immune complex. **BACKGROUND DATA:** There is a lack of information on LLLT effects in hemorrhagic injuries of high perfusion organs, and the relative efficacy of LLLT compared to anti-inflammatory drugs. **METHODS:** A controlled animal study was undertaken with 49 male Wistar rats randomly divided into seven groups. Bovine serum albumin (BSA) i.v. was injected through the trachea to induce an immune complex lung injury. The study compared the effect of irradiation by a 650-nm Ga-Al-As laser with LLLT doses of 2.6 Joules/cm<sup>2</sup> to celecoxib, dexamethasone, and control groups for hemorrhagic index (HI) and myeloperoxide activity (MPO) at 24 h after injury. **RESULTS:** The HI for the control group was 4.0 (95% CI, 3.7-4.3). Celecoxib, LLLT, and dexamethasone all induced significantly ( $p < 0.01$ ) lower HI than control animals at 2.5 (95% CI, 1.9-3.1), 1.8 (95% CI, 1.2-2.4), and 1.5 (95% CI, 0.9-2.1), respectively, for all comparisons to control. Dexamethasone, but not celecoxib, induced a slightly, but significantly lower HI than LLLT ( $p = 0.04$ ). MPO activity was significantly decreased in groups receiving celecoxib at 0.87 (95% CI, 0.63-1.11), dexamethasone at 0.50 (95% CI, 0.24-0.76), and LLLT at 0.7 (95% CI, 0.44-0.96) when compared to the control group, at 1.6 (95% CI, 1.34-1.96;  $p < 0.01$ ), but there were no significant differences between any of the active treatments. **CONCLUSION:** LLLT at a dose of 2.6 Joules/cm<sup>2</sup> induces a reduction of HI levels and MPO activity in hemorrhagic injury that is not significantly different from celecoxib. Dexamethasone is slightly more effective than LLLT in reducing HI, but not MPO activity.

PMID: 17508847 [PubMed - in process]

1: [Photomed Laser Surg.](#) 2007 Dec;25(6):487-94.  [Links](#)


## **Effect of lower-level laser therapy on rabbit tibial fracture.**

[Liu X](#), [Lyon R](#), [Meier HT](#), [Thometz J](#), [Haworth ST](#).

Musculoskeletal Functional Assessment Center, Medical College of Wisconsin, Milwaukee, Wisconsin.

**Objective:** The purpose of the study was to demonstrate the biological effects of low-level laser therapy (LLLT) on tibial fractures using radiographic, histological, and bone density examinations. **Methods:** Fourteen New Zealand white rabbits with surgically induced mid-tibial osteotomies were included in the study. Seven were assigned to a group receiving LLLT (LLLT-A) and the remaining seven served as a sham-treated control group (LLLT-C). A low-energy laser apparatus with a wavelength of 830 nm, and a sham laser (a similar design without laser diodes) were used for the study. Continuous outflow irradiation with a total energy density of 40 J/cm<sup>2</sup> and a power level of 200 mW/cm<sup>2</sup> was directly delivered to the skin for 50 seconds at four points along the tibial fracture site. Treatment commenced immediately postsurgery and continued once daily for 4 weeks. **Results:** Radiographic findings revealed no statistically significant fracture callus thickness difference between the LLLT-A and LLLT-C groups ( $p > 0.05$ ). However, the fractures in the LLLT-A group showed less callus thickness than those in LLLT-C group 3 weeks after treatment. The average tibial volume was 14.5 mL in the LLLT-A group, and 11.25 mL in the LLLT-C group. The average contralateral normal tibial volume was 7.1 mL. Microscopic changes at 4 weeks revealed an average grade of 5.5 and 5.0 for the LLLT-A group and the LLLT-C group, respectively. The bone mineral density (BMD) as ascertained using a grey scale (graded from 0 to 256) showed darker coloration in the LLLT-A group (138) than in the LLLT-C group (125). **Conclusion:** The study suggests that LLLT may accelerate the process of fracture repair or cause

increases in callus volume and BMD, especially in the early stages of absorbing the hematoma and bone remodeling. Further study is necessary to quantify these findings.

1: [Photomed Laser Surg.](#) 2007 Dec;25(6):467-73.  [Links](#)

## **Effect of Low-Level Laser Therapy on Inflammatory Reactions during Wound Healing: Comparison with Meloxicam.**

[Viegas VN](#), [Abreu ME](#), [Viezzler C](#), [Machado DC](#), [Filho MS](#), [Silva DN](#), [Pagnoncelli RM](#).

School of Dentistry, Laser Center, Pontifícia Universidade Católica do Rio Grande do Sul (PUCRS), Porto Alegre, RS, Brazil.

Objective: This study evaluated the action of low-level laser therapy (LLLT) on the modulation of inflammatory reactions during wound healing in comparison with meloxicam. Background Data: LLLT has been recommended for the postoperative period because of its ability to speed healing of wounds. However, data in the literature are in disagreement about its anti-inflammatory action. Methods: Standardized circular wounds were made on the backs of 64 Wistar rats. The animals were divided into four groups according to the selected postoperative therapy: group A-control; group B-administration of meloxicam; and groups C and D-irradiation with red ( $\lambda = 685 \text{ nm}$ ) and infrared ( $\lambda = 830 \text{ nm}$ ) laser energy, respectively. The animals were killed at 12, 36, and 72 h and 7 days after the procedure. Results: Microscopic analysis revealed significant vascular activation of irradiated sites in the first 36 h. Only group B showed decreases in the intensity of polymorphonuclear infiltrates and edema. Group D showed a higher degree of organization and maturation of collagen fibers than the other groups at 72 h. The animals in group C showed the best healing pattern at 7 days. The anti-inflammatory action of meloxicam was confirmed by the results obtained in this research. The quantification of interleukin-1beta (IL-1beta) mRNA by real-time polymerase chain reaction (PCR) did not show any reduction in the inflammatory process in the irradiated groups when compared to the other groups. Conclusions: LLLT improves the quality of histologic repair and is useful during wound healing. However, with the methods used in this study the laser energy did not minimize tissue inflammatory reactions.

1: [Photomed Laser Surg.](#) 2007 Dec;25(6):519-25.  [Links](#)

## **Effect of low-level laser therapy on skin fibroblasts of streptozotocin-diabetic rats.**

[Mirzaei M](#), [Bayat M](#), [Mosafa N](#), [Mohsenifar Z](#), [Piryaei A](#), [Farokhi B](#), [Rezaei F](#), [Sadeghi Y](#), [Rakhshan M](#).

Avicenna Hospital, Mazandran Medical University, Sari, Iran.

Objective: This study explored the effects of low-level laser therapy (LLLT) on cellular changes in cell culture and organ culture of skin from streptozotocin-diabetic (STZ-D) rats. Background Data: Growth of skin and its fibroblasts are impaired in diabetes. Therefore the healing of skin wounds is impaired in diabetic patients. The positive effects of LLLT on complications of diabetes in patients and animal models have been shown. Methods: Diabetes was induced in rats by streptozotocin 30 days

24

Internationellt momsnummer: SE556196619201.

Postgiro nr: 14723 - 1. **Bankgiro: 795-0504.**

**IRRADIA AB**, Box 27137, 102 52 Stockholm, Sweden  
Besöksadress: Norra Hamnvägen 3-5, 115 42 Stockholm, Sweden  
E-mail: laser@irradia.se

Telefon: 08-7672700 (-01, -03). Telefax: 08-7672706  
Bank: SE-Banken, Lidingö  
Hemsida: www.irradia.se

after its injection. Two sets of skin samples were extracted from skin under sterile conditions. Fibroblasts that were extruded from the samples were proliferated in vitro, and another set of samples were cultured as organ culture. A 24-well culture medium containing Dulbecco's modified minimum essential medium was supplemented by 12% fetal bovine serum. There were five laser-treated and five sham-exposed groups. A helium-neon laser was used, and 0.9-4 J/cm<sup>2</sup> energy densities were applied four times to each organ culture and cell culture. The organ cultures were analyzed by light microscopy and transmission electron microscopy examinations. Cell proliferation was evaluated by dimethylthiazol-diphenyltetrazolium bromide (MTT) assay. Results: Statistical analysis revealed that 4-J/cm<sup>2</sup> irradiation significantly increases the fibroblast numbers compared to the sham-exposed cultures (p = 0.046). Conclusion: It is concluded that LLLT resulted in a significant increase of fibroblast proliferation of STZ-D rats in vitro.

1: [Lasers Surg Med.](#) 2007 Oct;39(9):706-15.



[Links](#)

## Low-level light stimulates excisional wound healing in mice.

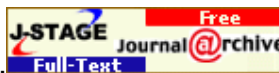[Demidova-Rice TN](#), [Salomatina EV](#), [Yaroslavsky AN](#), [Herman IM](#), [Hamblin MR](#).

Wellman Center for Photomedicine, Massachusetts General Hospital, Boston, Massachusetts 02114, USA.

**BACKGROUND:** Low levels of laser or non-coherent light, termed low-level light therapy (LLLT) have been reported to accelerate some phases of wound healing, but its clinical use remains controversial. **METHODS:** A full thickness dorsal excisional wound in mice was treated with a single exposure to light of various wavelengths and fluences 30 minutes after wounding. Wound areas were measured until complete healing and immunofluorescence staining of tissue samples was carried out. **RESULTS:** Wound healing was significantly stimulated in BALB/c and SKH1 hairless mice but not in C57BL/6 mice. Illuminated wounds started to contract while control wounds initially expanded for the first 24 hours. We found a biphasic dose-response curve for fluence of 635-nm light with a maximum positive effect at 2 J/cm<sup>2</sup>. Eight hundred twenty nanometer was found to be the best wavelength tested compared to 635, 670, and 720 nm. We found no difference between non-coherent 635±15-nm light from a lamp and coherent 633-nm light from a He/Ne laser. LLLT increased the number of alpha-smooth muscle actin (SMA)-positive cells at the wound edge. **CONCLUSION:** LLLT stimulates wound contraction in susceptible mouse strains but the mechanism remains uncertain. 2007 Wiley-Liss, Inc

PMID: 17960752 [PubMed - in process]

1: [J Vet Med Sci.](#) 2007 Aug;69(8):799-806.



[Links](#)

## The effect of low reactive-level laser therapy (LLLT) with helium-neon laser on operative wound healing in a rat model.

[Yasukawa A](#), [Hrui H](#), [Koyama Y](#), [Nagai M](#), [Takakuda K](#).

Institute of Biomaterials and Bioengineering, Tokyo Medical and Dental University, Tokyo, Japan. akio@abox6.so-net.ne.jp

The effect of low reactive-level laser therapy (LLLT) with a He-Ne laser on operative wound healing was investigated in a rat model. 10-millimeter surgical wounds were created on the backs of Sprague Dawley rats, and animals were assigned to one of eleven groups (n=5). Ten groups received either 8.5 mW or 17.0 mW irradiation of 15 seconds LLLT a day with one of five different irradiation frequencies, i.e. daily (from the 1st to 6th day following surgery), every other day (the 1st, 3rd, and 5th day), on only the 1st day, on only the 3rd day, and on only the 5th day; the 1st day

Internationellt momsnummer: SE556196619201.


Postgiro nr: 14723 - 1.

25

**Bankgiro: 795-0504.**

was the day following the surgery. The control group received no irradiation. A skin specimen was harvested from the dorsal thoracic region on the 7th day to measure the rupture strength. The control group had the lowest rupture strength (5.01 N), and the 17.0 mW every other day irradiation group had the highest rupture strength (13.01 N). Statistical differences were demonstrated in the 8.5 mW irradiation setting between the every other day irradiation group and the control group ( $p < 0.05$ ); and in 17.0 mW irradiation setting between the every day irradiation, the every other day, and the 1st day only groups vs. the control group ( $p < 0.01$ ). Histological examination demonstrated that wound healing in the 17.0 mW every other day irradiation group was promoted most significantly such as the prevention of excessive inflammation, increased formation of collagen fibers, and recovery in continuity of tissues. The control group showed poor wound healing and the other experimental groups showed intermediate healing. Thus LLLT with a He-Ne laser was found to promote the healing of operative wounds in the present rat model, in which the most favorable application of LLLT was the 17.0 mW setting of 15 seconds a day with a frequency of every other day.

PMID: 17827885 [PubMed - indexed for MEDLINE]

1: [Photomed Laser Surg.](#) 2007 Aug;25(4):245-9.  [Links](#)


## **Low-level laser therapy (GaAs lambda = 904 nm) reduces inflammatory cell migration in mice with lipopolysaccharide-induced peritonitis.**

[Correa F](#), [Martins RA](#), [Correa JC](#), [Iversen VV](#), [Joenson J](#), [Bjordal JM](#).

University Nove Julho, São Paulo, Brazil.

**OBJECTIVE:** This study was designed to study the effect of an infrared low-level laser (GaAs lambda = 904 nm, 4 mW) on inflammatory cell migration in lipopolysaccharide (LPS)-induced peritonitis in mice. **BACKGROUND DATA:** It has been suggested that red wavelengths of low-level laser therapy (LLLT) can exert anti-inflammatory effects, but little is known about the anti-inflammatory effects of infrared lasers. Peritonitis is a potentially life-threatening inflammatory condition that may be suitable for studying anti-inflammatory effects of infrared lasers. **METHODS:** Sixty male mice were randomly divided into five groups, and one group was given an intraperitoneal sterile saline injection. In the remaining four groups, peritonitis was induced by an intraperitoneal LPS injection. Animals in three of the LPS groups were irradiated at a single point over the peritoneum with doses of 3 J/cm(2), 7.5 J/cm(2), and 15 J/cm(2), respectively. The fourth group injected with LPS was an LPS-control group. **RESULTS:** At 6 hours after injection the groups irradiated with doses of 3 J/cm(2) and 7.5 J/cm(2) had a reduced number of neutrophil cells in the peritoneal cavity compared with the LPS-control group, and there were significant differences between the number of neutrophils in the peritoneal cavity between the LPS-control group and groups irradiated with doses of 3 J/cm(2) (-42%) and 7.5 J/cm(2) (-70%). In the group irradiated with 15 J/cm(2), neutrophil cell counts were lower than, but not significantly different from, LPS controls (-38%;  $p = 0.07$ ). At 24 hours after injection, both neutrophil and total leukocyte cell counts were lower in all the irradiated groups than in the LPS controls. The 3-J/cm(2) exposure group showed the best results at 24 hours, with reductions of 77% in neutrophil and 49% in leukocyte counts. **CONCLUSION:** Low-level laser therapy (904 nm) can reduce inflammatory cell migration in mice with LPS-induced peritonitis in a dose-dependent manner.

PMID: 17803379 [PubMed - indexed for MEDLINE]

1: [Lasers Surg Med.](#) 2007 Jul;39(6):534-42.  [Links](#)

Erratum in:

[Lasers Surg Med.](#) 2007 Dec;39(10):808. Timothy, Peter A Sr [corrected to Peter, Timothy A Sr].

## **Reciprocity of exposure time and irradiance on energy density during photoradiation on wound healing in a murine pressure ulcer model.**

[Lanzafame RJ](#), [Stadler I](#), [Kurtz AF](#), [Connelly R](#), [Peter TA Sr](#), [Brondon P](#), [Olson D](#).

Laser Center, Rochester General Hospital, Rochester, New York, USA. ray.lanzafame@viahealth.org

**BACKGROUND:** Energy density and exposure time reciprocity is assumed and routinely used in low-level light therapy (LLLT) regimens. This study examined dose reciprocity effects on wound healing. **METHODS:** Pressure ulcers were created on seven groups of C57/BL mice (n = 18). Photoradiation was administered (18 days; 5 J/cm<sup>2</sup>/day @ 670 nm) using a custom LED apparatus and treatment matrix varying both intensity and exposure. Control animals were treated similarly, without photoradiation. Ulcer staging was performed using a standardized scale. Changes in stage, wound area and wound closure rates were measured. Histology was performed. **RESULTS:** Photostimulatory effects at day 7 occurred with parameters of 125 seconds @ 40 mW x 1/day; 625 seconds @ 8 mWx1/day; 62.5 seconds @ 40 mWx2/day; and 312.5 seconds @ 8 mWx2/day; and at day 18 using 625 seconds @ 8 mW and 312.5 seconds @ 8 mWx2/day. Statistically significant increases in wound closure rates occurred using 625 seconds @ 8 mW; 62.5 seconds @ 40 mWx2/day; and 312.5 seconds @ 8 mWx2/day treatments. Mean ulcer grade scores were similar to controls. **CONCLUSIONS:** Varying irradiance and exposure time to achieve a specified energy density affects phototherapy outcomes in this model. Variation of exposure time and irradiance may account for conflicting results in the literature. Further studies of these effects are warranted. (c) 2007 Wiley-Liss, Inc.

PMID: 17659591 [PubMed - indexed for MEDLINE]

1: [Lasers Surg Med.](#) 2007 Jul;39(6):543-50.




[Links](#)

## **Low-level laser therapy for zymosan-induced arthritis in rats: Importance of illumination time.**

[Castano AP](#), [Dai T](#), [Yaroslavsky I](#), [Cohen R](#), [Apruzzese WA](#), [Smotrich MH](#), [Hamblin MR](#).

Wellman Center for Photomedicine, Massachusetts General Hospital, Boston, Massachusetts 02114, USA.

**BACKGROUND:** It has been proposed for many years that low-level laser (or light) therapy (LLLT) can ameliorate the pain, swelling, and inflammation associated with various forms of arthritis. Light is thought to be absorbed by mitochondrial chromophores leading to an increase in adenosine triphosphate (ATP), reactive oxygen species and/or cyclic AMP production and consequent gene transcription via activation of transcription factors. However, despite many reports about the positive effects of LLLT in arthritis and in medicine in general, its use remains controversial. For all indications (including arthritis) the optimum optical parameters have been difficult to establish and so far are unknown. **METHODS:** We tested LLLT on rats that had zymosan injected into their knee joints to induce inflammatory arthritis. We compared illumination regimens consisting of a high and low fluence (3 and 30 J/cm<sup>2</sup>), delivered at high and low irradiance (5 and 50 mW/cm<sup>2</sup>) using 810-nm laser light daily for 5 days, with the positive control of conventional corticosteroid (dexamethasone) therapy. **RESULTS:** Illumination with 810-nm laser was highly effective (almost as good as dexamethasone) at reducing swelling and a longer illumination time (10 or 100 minutes compared to 1 minute) was more important in determining effectiveness than either the total fluence delivered or the irradiance. LLLT induced reduction of joint swelling correlated with reduction in the inflammatory marker serum prostaglandin E<sub>2</sub> (PGE<sub>2</sub>). **CONCLUSION:** LLLT with 810-nm laser is highly effective in treating inflammatory arthritis in this model. Longer illumination times were more effective than short times regardless of total fluence or irradiance. These data will be of value in designing clinical trials of LLLT for various arthritides. (c) 2007 Wiley-Liss, Inc.

1: [Clin Oral Investig.](#) 2007 Jul 12 [Epub ahead of print]  [Links](#)


## **Effect of defocused infrared diode laser on salivary flow rate and some salivary parameters of rats.**

[Simões A](#), [Nicolau J](#), [de Souza DN](#), [Ferreira LS](#), [de Paula Eduardo C](#), [Apel C](#), [Gutknecht N](#).

Oral Biology Research Center, Department of Dental Materials, Faculty of Dentistry, University of São Paulo, 05508-000, São Paulo, Brazil.

This study aims to investigate whether infrared diode low-level laser therapy (LLLT) increased salivary flow rate and altered pH value, protein concentration, and peroxidase and amylase activities in saliva of rats. Wistar rats were used and divided into three groups. Experimental groups (A and B) had their parotid, submandibular and sublingual glands submitted to diode laser, 808-nm wavelength, on two consecutive days. The dose results were 4 and 8 J/cm<sup>2</sup>, respectively. A red guide light was used to visualize the irradiated area. Group C was irradiated only with red pilot beam and served as control. The saliva samples were collected after each irradiation step (first and second collection days) and 1 week after the first irradiation (seventh day). Statistical analysis was performed, and differences were observed according to different days of salivary collection. The results showed that salivary flow rate for groups A and B was higher on the seventh day if it is compared to data obtained for the first day ( $p < 0.05$ ). LLLT applications on salivary glands are a therapy procedure that requires further studies.

PMID: 17624559 [PubMed - as supplied by publisher]

1: [Lasers Med Sci.](#) 2007 Jul 10 [Epub ahead of print]  [Links](#)

## **Effects of laser irradiation on the release of basic fibroblast growth factor (bFGF), insulin like growth factor-1 (IGF-1), and receptor of IGF-1 (IGFBP3) from gingival fibroblasts.**

[Saygun I](#), [Karacay S](#), [Serdar M](#), [Ural AU](#), [Sencimen M](#), [Kurtis B](#).

Department of Periodontology, Gulhane Military Medical Academy, Etlik, Ankara, 06018, Turkey, saygunisil@yahoo.com.

Various studies have shown biostimulation effects of laser irradiation by producing metabolic changes within the cells. Little is known about the biological effect of laser irradiation on the oral tissues. Among the many physiological effects, it is important to recognize that low-level laser therapy (LLLT) may affect release of growth factors from fibroblasts. Therefore, the aim of the present study was to determine whether the laser irradiation can enhance the release of basic fibroblast growth factor (bFGF), insulin-like growth factor-1 (IGF-1), and receptor of IGF-1 (IGFBP3) from human gingival fibroblasts (HGF). The number of all samples in the study were 30, and the samples were randomly divided into three equal groups; In the first group (single dose group), HGF were irradiated with laser energy of 685 nm, for 140 s, 2 J/cm<sup>2</sup> for one time, and in the second group, energy at the same dose was applied for two consecutive days (double dose group). The third group served as nonirradiated control group. Proliferation, viability, and bFGF, IGF-1, IGFBP3 analysis of control and irradiated cultures were compared with each other. Both of the irradiated groups revealed higher proliferation and viability in comparison to the control group. Comparison of the single-dose group with the control group revealed statistically significant increases in bFGF ( $p < 0.01$ ) and IGF-1 ( $p < 0.01$ ), but IGFBP3 increased insignificantly ( $p > 0.05$ ). When the double dose group was compared with the control group, significant increases were determined in all of the parameters ( $p < 0.01$ ). In the comparison of the differences between the two irradiated groups (one dose and two doses), none of the parameters displayed any statistically significant difference ( $p > 0.05$ ). In both of the laser groups, LLLT increased the

Internationellt momsnummer: SE556196619201.

Postgiro nr: 14723 - 1. **Bankgiro: 795-0504.**

cell proliferation and cell viability. The results of this study showed that LLLT increased the proliferation of HGF cells and release of bFGF, IGF-1, and IGFBP3 from these cells. LLLT may play an important role in periodontal wound healing and regeneration by enhancing the production of the growth factors.

PMID: 17619941 [PubMed - as supplied by publisher]

1: [Probl Tuberk Bolezn Legk.](#) 2007;(8):50-3. [Links](#)

## **[Efficiency of a combination of haloaerosols and helium-neon laser in the multimodality treatment of patients with bronchial asthma]**

[Article in Russian]

[Faradzheva NA.](#)

A hundred and thirty-eight patients with infection-dependent bronchial asthma, including 73 with moderate persistent asthma and 65 with severe persistent one, were examined. Four modes of a combination of traditional (drug) therapy (DT) and untraditional (halotherapy (HT) and endobronchial helium-neon laser irradiation (ELI) one were used. The efficiency of the treatment performed was evaluated, by determining the time course of clinical symptoms of the disease on the basis of scores of their magnitude and the patients' condition. The findings indicated that in moderate persistent asthma, both HT and ELI in combination with DT exerted an equal therapeutic effect, which provided a good and excellent condition in 83.3% of cases. In severe persistent asthma, such a condition was achieved in 93.75% of cases only when multimodality treatment involving DT, HT, and ELI had been performed.

PMID: 17915468 [PubMed - indexed for MEDLINE]

Astma

□ 1: [Urologija.](#) 2007 May-Jun;(3):50-4, 56. [Links](#)

## **[Efficacy of low-intensity laser radiation and antibacterial therapy in the treatment of chronic prostatitis in the presence of sexually transmitted infections]**

[Article in Russian]

[Neimark AI](#), [Khrianin AA](#), [Safina ON](#), [Neimark BA](#), [Kondrat'eva luS.](#)

We studied 94 patients with chronic prostatitis (CP) in combination with urogenital chlamydiasis. The patients were divided into three groups. Group 1 consisted of 32 patients with bacterial prostatitis and sexually transmitted infection (STI). They were treated with fromilid in a dose 500 mg twice a day. Group 2 (n = 27) received also low-intensity laser radiation (LILR) on the prostatic gland. Group 3 patients (n = 35) with abacterial prostatitis were given fromilid (500 mg twice a day). We studied prostatic hemodynamics with color doppler mapping. A specific feature of prostatic vascularisation in CP and STI versus healthy subjects is heterogeneous decline of vessels density in ischemic zones with parallel decrease in these vessels diameter. A peripheral prostatic zone in CP patients with STI was characterized by lower vascularisation than central one. This deteriorates the course of the disease. The results of the study show that adjuvant LILR in CP patients with STI raises efficacy of therapy by 11%. Investigation of prostate vascularisation and hemodynamics of its vessels in CP patients with STI using transrectal ultrasonography and dopplerography provide detailed information about prostatic structure allowing for lesion zones. This facilitates choice of an optimal complex treatment with application of LELR in peripheral inflammation of the prostate.

1: [Srp Arh Celok Lek.](#) 2007 May-Jun;135(5-6):257-63. [Links](#)

## **[Influence of low-intensity laser therapy on spatial perception threshold and electroneurographic finding in patients with diabetic polyneuropathy]**

[Article in Serbian]

### **Perić Z.**

**INTRODUCTION:** Low-intensity laser therapy (LILT) can be applied in cases when patients with diabetic polyneuropathy (DPN) suffer from chronic severe neuropathic pain. **OBJECTIVE:** We wanted to analyse influence of LILT on spatial perception threshold (SPT) and electroneurographic (ENG) parameters in patients with painful DPN. **METHOD:** We analysed 45 patients (25 males), average age 54.3 years (54.3 +/- 10.9), with clinical and ENG signs of painful DPN. The patients were divided into two groups: A and B. Group A consisted of 30 patients with DPN who had 30 LILT treatments over the period of 12 weeks and group B consisted of 15 patients with DPN who received only vitamin therapy per os within the same period. Prior to and after 12 weeks of treatment, the following ENG parameters were determined using surface electrodes: motor (MCV) and sensory conduction velocities (SCV) values (in m/s) of nervus (n.) peroneus (NP), n. tibialis (NT) and n. medianus (NM) and their motor distal latency (MDL) values (in ms). SPT value (score as number from 1 to 8) was determined with Tactile Circumferential Discriminator on dorsal part of foot's big toe skin. For statistical analysis, we used Student's t-test and Pearson correlation (sig. 2 tailed) study. **RESULTS;** We registered statistically significant difference between SPT ( $p < 0.01$ ) values prior to (5.25 +/- 1.11) and after (4.87 +/- 0.90) LILT, as well as NMMCV ( $p < 0.05$ ) values prior to (47.18 +/- 5.08) and after (49.12 +/- 3.72) LILT. Besides, we registered, only after LILT, statistically significant correlation between SPT and NMDML ( $p < 0.01$ ) values and also between SPT and NMSCV ( $p < 0.05$ ) values. The differences and correlations between other analysed parameters before and after treatments were not significant ( $p > 0.05$ ). **CONCLUSION:** In this study we registered significant decrease of SPT and increase of NMMCV after LILT and that indicated a favourable effect of this treatment in analysed patients with painful DPN. In our opinion these results need further investigation.

PMID: 17633309 [PubMed - indexed for MEDLINE]